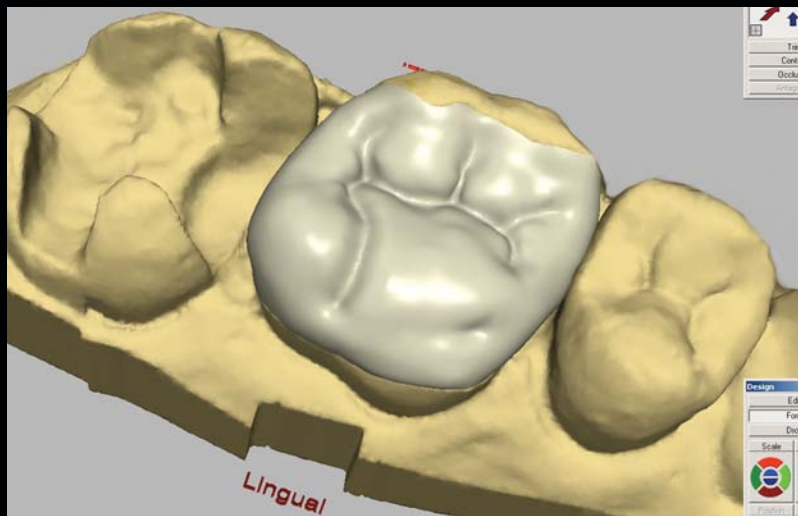


CONTINUING EDUCATION **XX**

# AESTHETIC QUADRANT DENTISTRY USING A CHAIRSIDE CAD/CAM SYSTEM: A CASE PRESENTATION

James Klim, DDS\*



*There are numerous CAD/CAM technologies available today for the production of highly aesthetic restorations with strength and precision. Laboratory-based CAD/CAM systems typically require the patient to receive a provisional restoration and then return to the dental office for a second visit for placement of the definitive restoration upon receipt from the laboratory. Chairside systems, as described in the following case presentation, allow excellent benefits to be achieved in one patient visit. Thus, this case presentation describes the associated sequences for single-visit, in-office CAD/CAM quadrant dentistry.*

#### Learning Objectives:

This article discusses an effective protocol for the use of CAD/CAM restorations in the aesthetic replacement of amalgam fillings. Upon reading this article, the reader should have:

- Greater awareness of the chairside CAD/CAM processes and procedures used to fabricate single-visit, all-ceramic inlays, onlays, and partial crowns.
- An understanding of the scanning and machining concepts as well as related hardware and software tools.

*Key Words: quadrant, posterior, CAD/CAM, chairside, single-visit*

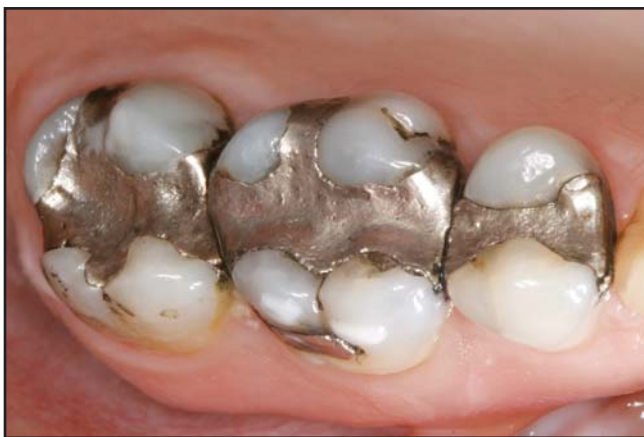\*Private practice, Santa Rosa, CA.

James Klim, DDS • 2755 Mendocino Avenue #204, Santa Rosa, CA 95403  
Tel: 707-544-7645 • E-mail: smileguy@sonic.net

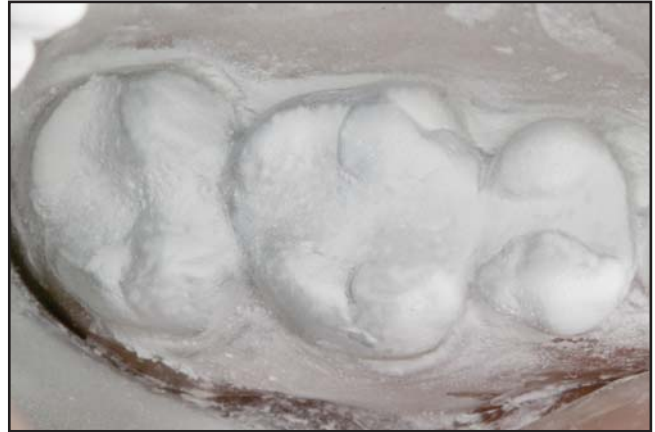## Practical Procedures & AESTHETIC DENTISTRY

Systems used for the chairside fabrication of CAD/CAM restorations (ie, Cerec 3D, Sirona Dental Systems, Charlotte, NC) were first introduced to the dental market in 1987. Developed as an alternative to pressed and refractory ceramics as well as to indirectly fabricated CAD/CAM crowns and bridges (eg, Procera, Nobel Biocare, Yorba Linda, CA; Cercon, Dentsply Ceramco, York, PA), the restorations fabricated chairside had a reputation often characterized by insufficient fit and aesthetics. In 2003, however, the system received three-dimensional (3-D) imaging software that enabled more efficient design of a given restoration. Prior to this upgrade, on-screen CAD was tedious, as the restoration was displayed as two-dimensional slices of data on the computer screen. This planar view made it difficult for the operator to visualize the restoration as a whole during its design, as the practitioner could not immediately see, for example, what effect changing the height of a cusp would have on the crown as a whole.

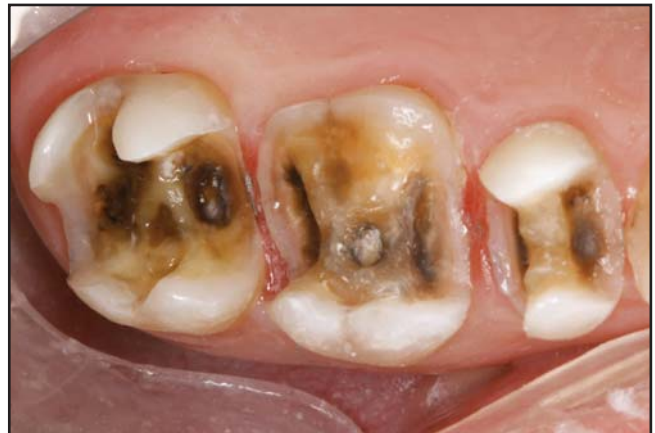Using the software tools of the current Cerec system (ie, Sirona Dental Systems, Charlotte, NC), the practitioner has the benefit of working with a computerized image of a complete tooth in 360° detail. Additionally, the clinician can modify and manipulate the restoration from any angle or position (ie, mesial, distal, occlusal,



**Figure 1.** Preoperative occlusal view of three extensive amalgam restorations on teeth #2(17) through #4(15).



**Figure 2.** The teeth to be restored were coated with optical powder, and their images were captured and stored in the computer as a correlate, or reference, for the CAD software.

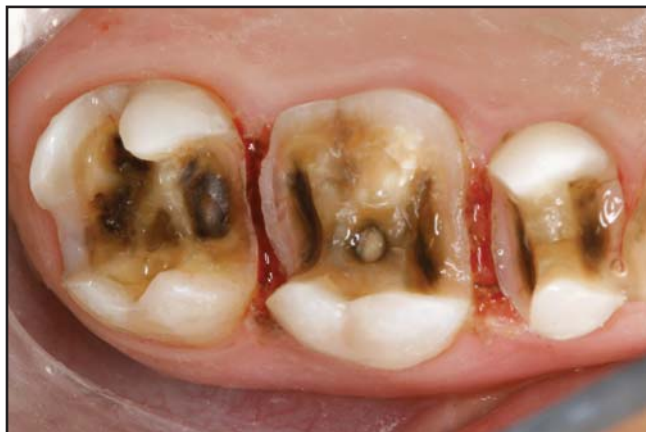

**Figure 3.** The amalgam was removed with a carbide bur in an electric handpiece. The margins were completed with finishing diamonds.

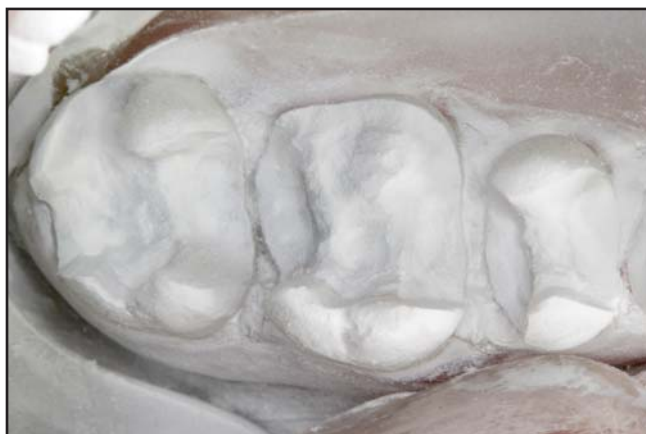buccal, lingual) by simply manipulating it with the mouse. This article will highlight the workflow of the chairside CAD/CAM approach and document potential outcomes using a detailed case presentation.

### Concept Overview

Utilizing in-office CAD/CAM technology, clinicians can design, fabricate, and place all-ceramic inlays, onlays, crowns, and veneers in a single patient visit. The ceramic restorations produced by this method have demonstrated excellent fit,<sup>1-3</sup> strength,<sup>4,7</sup> and longevity.<sup>8-10</sup> The clinician prepares the tooth using conventional tools



**Figure 4.** Once removal of all amalgam was achieved, a diode laser was used to trough for margin exposure and debride unhealthy gingival tissue.

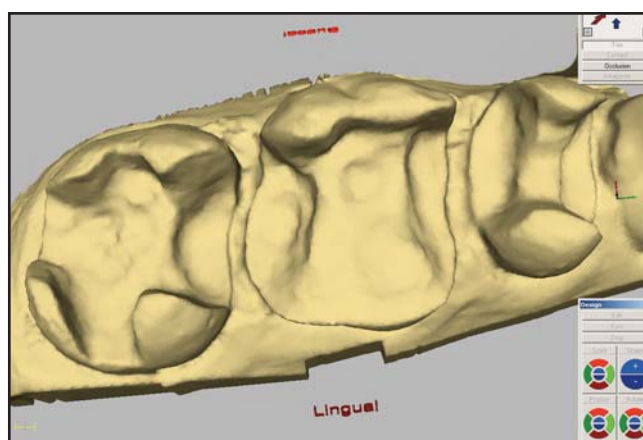


**Figure 5.** The prepared teeth were powdered and readied for an optical impression to be taken.

and methods. Basic preparation design principles consist of: flared interproximal box walls set 90° to the external surfaces; a slight flare to parallel internal walls with occlusal cavosurface margins (computer will block out undercuts); and a 3-mm-wide isthmus with a porcelain bulk depth of 2 mm in groove areas and 2 mm in cusp replacement. The author uses depth grooves with pre-measured burs prior to preparations to assist in adequate reduction criteria. Margin design can be the clinician's choice of either shoulder or chamfer.

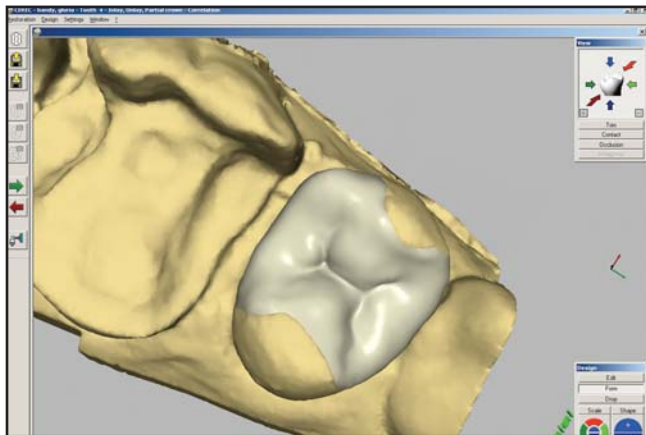
Once tooth preparation has been accomplished, a three-dimensional optical impression is taken with an

infrared, intraoral camera. Whereas impressions using conventional methods (ie, impression material and tray) require several minutes to produce, this optical impression is a time-saving endeavor, generating results that are displayed immediately on a color monitor. The software that drives the Cerec System (Sirona Dental Systems, Charlotte, NC) contains a comprehensive database of natural tooth anatomies for each tooth. Using this information in combination with the specific parameters of the preparation, the software develops a proposed restoration designed to fit the preparation precisely. The CAD software can also account for the occlusal contacts from a bite registration of the opposing tooth while it designs the restoration. This feature helps maintain proper form and functional occlusion. When the clinician is satisfied with the design, the restoration is milled from a single, solid ceramic block. The newer generation block selections have more color and transparency options. The leucite-crystal ProCAD (Ivoclar Vivadent, Amherst, NY) blocks correspond to the shade guide colors with either a high or low translucency for each shade. The Paradigm (3M Espe, St. Paul, MN) composite blocks have multiple shades. Additionally, the tri-layered blocks incorporate cervical, body, and incisal colors within the block capable of being manipulated on the computer

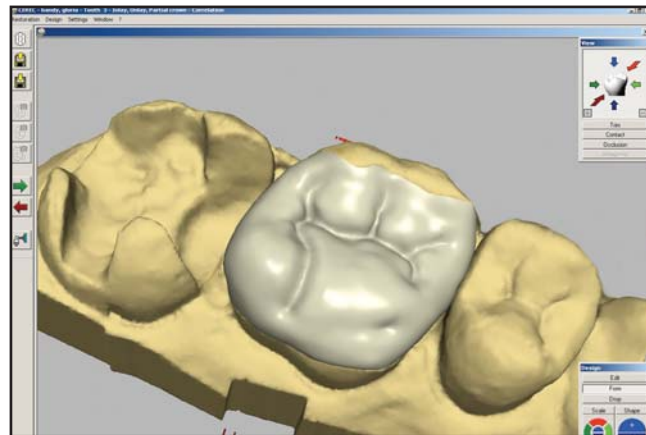


**Figure 6.** View of the virtual impression of all three prepared posterior teeth.

## Practical Procedures & AESTHETIC DENTISTRY



**Figure 7.** View of the virtual inlay of tooth #4(15) as proposed by the CAD/CAM software.



**Figure 8.** Occlusal view of virtual tooth #3(16).

to the desired transition zones. Once milled and finished, the resulting restoration is then bonded in place with a conventional resin-based bonding agent.

### Case Presentation

The following case demonstrates the application of chair-side all-ceramic CAD/CAM inlays. A 52-year-old female presented with the chief desire to replace her existing amalgam restorations due to concern with their long-term affect on her health and the unsightly discoloration of her teeth (Figure 1). The patient was relieved to find that full-coverage crowns were not her only option, as the proposed all-ceramic onlays would permit greater preservation of her natural tooth structure. She was also appreciative of the fact that the entire quadrant could be completed in one appointment.

The clinician chose to design the restorations using a CAD/CAM design method called "correlation," which is the duplication of the patient's existing tooth morphology. This required either a preoperative optical impression of a study model (waxup if needed) or by the capture of the patient's intraoral conditions with the system's intraoral camera (Figure 2). The benefit of the correlation method was the replication of accurate occlusal dimensions and proximal line angles.<sup>11</sup> The software offers

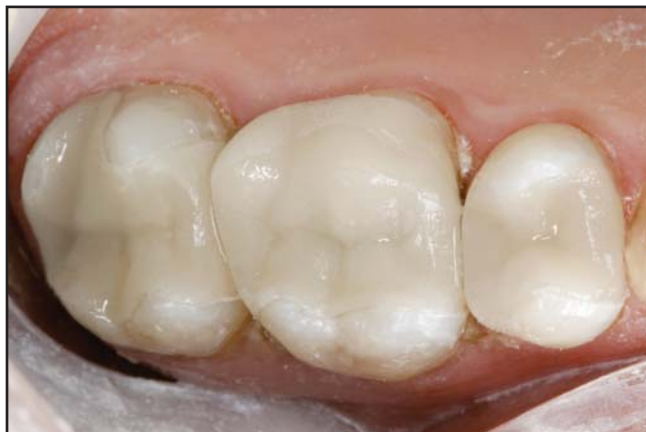several design tools to further refine the restoration and retain the accuracy of the occlusal contacts. Since the correlation method utilized a digital image of the patient's preoperative occlusal morphology to propose a restoration design, the resultant proposal was extremely precise, necessitating little if any occlusal adjustments to the milled restorations.<sup>11</sup>

### Preparation and Optical Impression

As previously described, the preparation method was similar to that of a traditional laboratory-fabricated restoration (Figure 3). For this case, however, a diode laser (ie, Odyssey, Ivoclar Vivadent, Amherst, NY) was used in order to assist with the removal of interproximal diseased tissues without damaging the connective tissue attachment (Figure 4). Soft tissue management with the laser also enabled the clinician to effectively expose the interproximal margins. This technique would create supragingival margins that would help facilitate optimal seating of the definitive restorations.

Capturing the optical impression was accomplished by the clinician, who applied a thin coating of fine titanium dioxide powder to the prepared teeth and surrounding gingival tissues (Figure 5). The titanium dioxide is an ideal white pigment due to its brightness and high





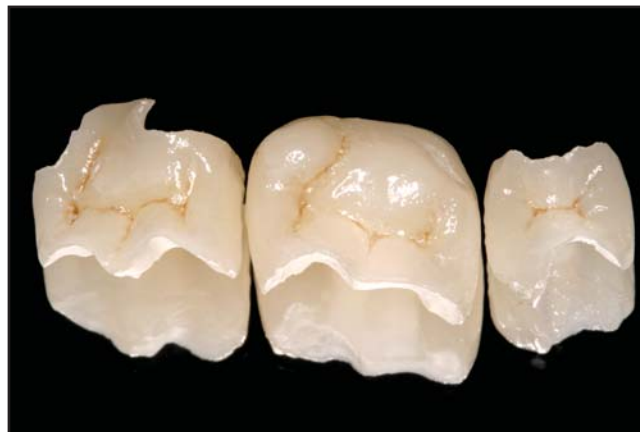**Figure 9.** Try-in of all three ProCAD (Ivoclar Vivadent, Amherst, NY) inlay restorations following the completion of the milling process.

refractive index. To obtain the optical impression, the infrared camera was placed just above and perpendicular to the powdered preparations. A real-time view of the image was displayed on the monitor, and when the clinician was satisfied with the positioning of the camera, a single tap on a footswitch captured the fixed image. The software is able to present multiple images for full-quadrant display. The image of the preparations was immediately displayed on screen and would be used by the CAD/CAM software to propose the design of the inlay restorations (Figure 6).

#### **Restoration Design and Fabrication**

While the patient sat in the chair, the computer created and displayed on the monitor a virtual die that had the appearance of a stone model (Figure 7). Designing the virtual restoration was similar to that traditionally performed at the laboratory: the die margins were trimmed, and the restoration was designed. Rather than physically building up the restoration using layers of porcelain, however, the clinician was presented with a fully contoured 3-D model of the restoration to refine.

By accessing a comprehensive database of natural tooth structures, the clinician was able to assess the design proposed by the computer and to verify its fit in



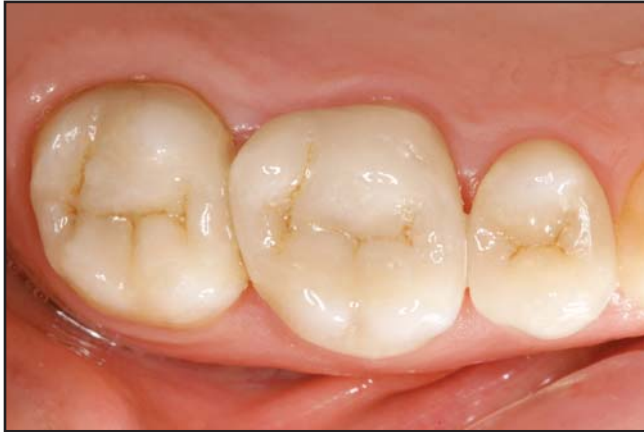**Figure 10.** After try-in and occlusal verification, ProCAD (Ivoclar Vivadent, Amherst, NY) stain and glaze were used to add lifelike characterization to the definitive restorations.

relation to the preparation, the gingival margins, and the neighboring teeth, as well as the occlusion (Figure 8). Any refinements deemed necessary by the dental professional were accomplished with the computer software's design tools. Using the CAD software, the practitioner could form the desired interproximal contacts and verify occlusal relationships prior to milling. The image of the restoration on the computer screen would be reproduced in the milling process. According to the aforementioned process, the author can typically design a single restoration in 2 to 5 minutes, depending on the complexity of the case at hand.

As applied in this posterior quadrant, each restoration was designed while its neighbor was being milled. The ability of this system (ie, Cerec, Sirona Dental Systems, Charlotte, NC) to perform the design and milling phases in tandem allowed for productive workflow. In this case study, restorations were designed starting from the second premolar to the second molar.

Once the restorations are milled, they are tried-in for fit, and interproximal contacts are verified (Figure 9). At this point, the practitioner had to choose to either polish the restoration only or to stain and glaze it for further characterization. Although staining and glazing of the definitive restoration was not required, doing so would

## Practical Procedures & AESTHETIC DENTISTRY



**Figure 11. Occlusal view of the finished Cerec/ProCAD (Ivoclar Vivadent, Amherst, NY) restorations postoperation one week demonstrating natural-looking aesthetics.**

enhance its aesthetics. To integrate the restoration with the natural dentition, the clinician selected a ProCAD (Ivoclar Vivadent, Amherst, NY) ceramic block by first identifying the coronal cusp color and opacity of the patient's natural dentition. The body and cervical areas were then blended with ceramic stain. As the intent of this case was to produce highly aesthetic restorations that would be indistinguishable with the patient's natural dentition, characterization was achieved with a one-step application of ProCAD (Ivoclar Vivadent, Amherst, NY) stain and glaze (Figure 10).

### Restoration Placement

Prior to bonding of the restorations, syringable retraction paste (ie, Expasyl, Kerr/Sybron, Orange, GA) was placed to prevent soft tissue fluid seepage by opening the sulcus. Even though the diode laser provides excellent hemostasis, the author uses this paste as additional assurance to avoid cervical fluid contamination during the bonding process. A self-etching resin cement (ie, Multilink, Ivoclar Vivadent, Amherst, NY) was selected for bonding of the definitive restorations.

The total treatment time for all three restorations was approximately 140 minutes by utilizing the aforementioned CAD/CAM technique. The result was the

delivery of three accurate, aesthetic, all-ceramic restorations that satisfied the patient's expectations and the clinician's requisites (Figure 11).

### Conclusion

In the author's experience, the Cerec 3D System (Sirona Dental Systems, Charlotte, NC) is well suited for single-visit quadrant dentistry. The technology has definitely improved in the years since its inception, with much enhancement and refinement in ease-of-use and materials in recent years. The one-appointment approach increases practice profitability with reduced overall treatment time. Although this approach will not replace all laboratory procedures, it is a practical CAD/CAM system for providing patients with all-ceramic indirect restorations that are at once conservative, durable, and aesthetically equivalent to natural dentition.

### Acknowledgment

*The author declares no financial interest in any of the products referenced herein.*

### References

1. Estafan D, Dussetschleger F, Agosta C, Reich S. Scanning electron microscope evaluation of CEREC II and CEREC III inlays. *Gen Dent* 2003;51(5):450-454.
2. Nakamura T, Dei N, Kojima T, Wakabayashi K. Marginal and internal fit of CEREC 3 CAD/CAM all-ceramic crowns. *Int J Prosthodont* 2003;16(3):244-248.
3. Bindl A, Mörmann WH. Clinical and SEM evaluation of all-ceramic chairside CAD/CAM-generated partial crowns. *Eur J Oral Sci* 2003;111(2):163-169.
4. Bremer BD, Geursten W. Molar fracture resistance after adhesive restoration with ceramic inlays or resin-based composites. *Am J Dent* 2001;14(4):216-220.
5. Hickel R, Manhart J. Longevity of restorations in posterior teeth and reasons for failure. *J Adhes Dent* 2001;3(1):45-64.
6. Tinschert J, Zwez D, Marx R, Anusavice KJ. Structural reliability of alumina, feldspar, leucite, mica, and zirconia-based ceramics. *J Dent* 2000;28(7):529-535.
7. Chen HY, Hickel R, Setcos JC, Kunzelmann KH. Effects of surface finish and fatigue on the fracture strength of CAD/CAM and pressed-ceramic crowns. *J Prosthet Dent* 1999;82(4):468-475.
8. Posselt A, Kerschbaum T. Longevity of 2328 chairside CEREC inlays and onlays. *Int J Comput Dent* 2003;6(3):231-248.
9. Otto T, DeNisco S. Computer-aided ceramic restorations: A 10-year prospective clinical study of CEREC CAD/CAM inlays and onlays. *Int J Prosthodont* 2002;15(2):122-128.
10. Martin N, Jedykiewics NM. Clinical performance of CEREC ceramic inlays: A systematic review. *Dent Mater* 1999;15(1):54-61.
11. Simon J, Schmidt B. New CAD/CAM system combines simplicity with sophistication. *Contemporary Esthetics*, 2003;7(9) (Suppl):15-22.

# CONTINUING EDUCATION (CE) EXERCISE No. X



To submit your CE Exercise answers, please use the answer sheet found within the CE Editorial Section of this issue and complete as follows: 1) Identify the article; 2) Place an X in the appropriate box for each question of each exercise; 3) Clip answer sheet from the page and mail it to the CE Department at Montage Media Corporation. For further instructions, please refer to the CE Editorial Section.

The 10 multiple-choice questions for this Continuing Education (CE) exercise are based on the article "Aesthetic quadrant dentistry using a chairside CAD/CAM system: A case presentation," by James Klim, DDS. This article is on Pages 000-000.

1. In what year were CAD/CAM restorations first introduced to the dental market?
  - a. 1995.
  - b. 1987.
  - c. 1983.
  - d. 1990.
2. CAD/CAM restorations were developed as an alternative to which of the following?
  - a. Pressed ceramics.
  - b. Refractory ceramics.
  - c. Indirectly fabricated CAD/CAM crowns and bridges.
  - d. All of the above.
3. Using current CAD/CAM system software, the clinician can manipulate the restoration from which angle or position?
  - a. Mesial and/or distal.
  - b. Occlusal, buccal, and/or lingual.
  - c. Both a and b.
  - d. Neither a nor b.
4. Which CAD/CAM design method involves the duplication of the patient's existing tooth morphology?
  - a. Correling.
  - b. Duplication.
  - c. Correlation.
  - d. None of the above.
5. In this case study, restorations were designed starting from which tooth?
  - a. The first premolar.
  - b. The second premolar.
  - c. The second molar.
  - d. None of the above.
6. To obtain the optical impression, how was the infrared camera placed in relation to the powdered preparations?
  - a. Above and parallel.
  - b. Above and perpendicular.
  - c. Below and parallel.
  - d. Below and perpendicular.
7. Since the correlation method utilized a digital image of the patient's occlusal morphology, the resulting proposal was?
  - a. Extremely precise.
  - b. Somewhat precise.
  - c. Not at all precise.
  - d. None of the above.
8. What was placed prior to the bonding of the restorations to prevent soft tissue fluid seepage?
  - a. Retractory syringe paste.
  - b. Syringe protraction paste.
  - c. Syringe retraction paste.
  - d. Protractory syringe paste.
9. Using the CAD/CAM system can be described as which of the following?
  - a. Conservative.
  - b. Durable.
  - c. Aesthetically equivalent to natural dentition.
  - d. All of the above.
10. What 2003 CAD/CAM advancement enabled more efficient design of a given restoration?
  - a. Three-dimensional imaging.
  - b. Flat-panel monitors.
  - c. Two-dimensional imaging.
  - d. Faster processing.