


A Supplement to
Compendium
of Continuing Education in Dentistry®

BIOGENERIC
Technology

The **Next Generation**
of Chairside Esthetics



Clinical Applications for Chairside CAD/CAM Dentistry

The technology growth in computer-aided design and manufacturing (CAD/CAM) digital imaging, software design, and milling has created an equivalent alternative to laboratory-generated indirect ceramic restorations.¹⁻³ The digitally milled restorative process has been available for over 20 years. As with most technologies, CAD/CAM chairside technology has evolved and been perfected, particularly since CEREC 3D arrived on the clinical scene. The critical perception of this technology needs to be reconsidered with the evidence now seen with ease of digital capture, software virtual design, precision of milling and fit,¹⁻³ and availability of esthetic ceramic blocks.

Preset design parameters provide the operator with full control over interproximal contact firmness, occlusal contact strength, and spacer cement gap.

CAD/CAM milled restorations are ideal for conservative amalgam replacement (Figure 1). Patients in particular prefer the conservative nature of preparation design, which preserves more of the natural tooth structure

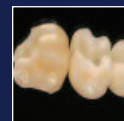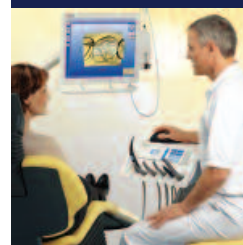
compared with a crown and equal longevity of gold.⁴⁻⁷ In most clinical cases, the restorative procedure is completed in 1 appointment rather than placing a provisional followed by a second appointment for cementing the restoration. With proper adhesive technique, the bonded CAD/CAM conservative restorative assembly recaptures virgin tooth strength.⁸⁻¹⁰

Preparation criteria for inlay/onlay CAD/CAM restoration requires clean crisp margins, 3° to 6° of occlusal draw, and flared interproximal box walls set 90° to the external surfaces (Figure 2). Digital capturing is enhanced with reflective medium (Figure 3). For the most complete digital design, teeth adjacent to the preparation are captured so the software has more occlusal terrain to work with. The addition of a digital bite registration will complete the records the computer needs to propose an anatomically correct and functional restoration design.¹¹⁻¹³

The software is designed to precisely stitch together multiple digital images when needed and propose a virtual die. Once the digital die is approved, the next step in the design process is outlining the preparation with the automatic margin finder.

The biogeneric software takes over the design process for inlay and onlay

James Klim DDS,
Restorative Practice
Director, CADStar, Institute
for Advanced Dental
CAD/CAM Education
Santa Rosa, California
www.cadstar.org



restorations by drawing on examples of hundreds of natural teeth in the software's data bank.¹⁴ It takes about 25 seconds for the computer to automatically finalize the proposed virtual restoration (Figure 4). The operator only needs to verify the proposed occlusal and proximal contacts and the restoration is ready to mill.

Preset design parameters provide the operator with full control over interproximal contact firmness, occlusal contact strength, and spacer cement gap. Before milling, the operator is able to approve the virtual 3D prototype for design satisfaction. When the parameters are calibrated according to the operator's clinical preferences, the resulting milled restorations will virtually drop into the preparation with closed margins, well-shaped interproximal design, and occlusal contacts that will require minimal adjustment.

The esthetic challenges of historical CAD/CAM restorations have been solved with a wider selection of color, transparency, and the multilay-

ered blocks (Figure 5). The color selection process is most effectively accomplished by choosing from the incisal or cuspal portion of the adjacent teeth. Before milling, the proposed restoration can be positioned in the virtual 3D block to reproduce the cervical to coronal gradation desired when using a layered block.

Once the restoration is milled (3-7 minutes with the most recent CEREC MC XL milling unit), it is tried in for clinical approval before finishing (Figure 6). With the precision of digital imaging and milling of the MC XL unit (7.5 μ m milling resolution), the operator can expect the marginal precision of gold.¹⁵ The current CEREC system will accomplish this precision on a regular basis with proper indirect preparation design and digital capturing technique.

Another advantage of a milled ceramic over pressed or laboratory-fabricated ceramics is the inherent quality of the material. Milled ceramic blocks have the lowest probability of internal flaws

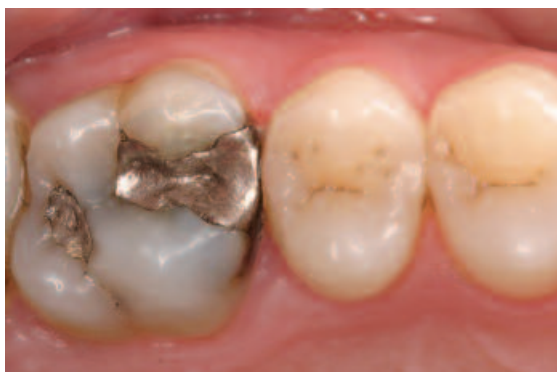

Figure 1—First molar with recurrent caries and cold sensitivity.

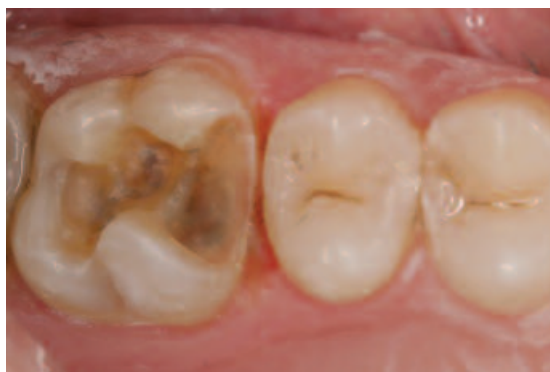

Figure 2—Completed CEREC preparation. Undercuts are blocked out by the CEREC software. Mesial margin exposed with diode laser.

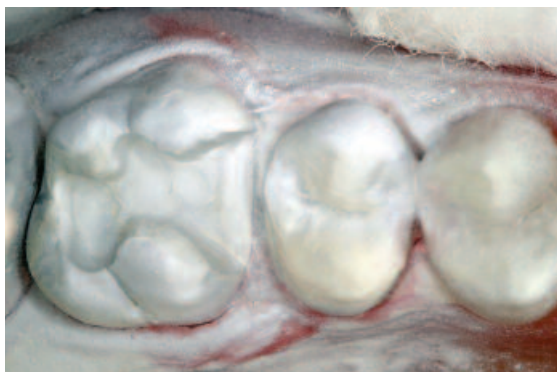

Figure 3—Digital enhancement with application of a reflective medium.

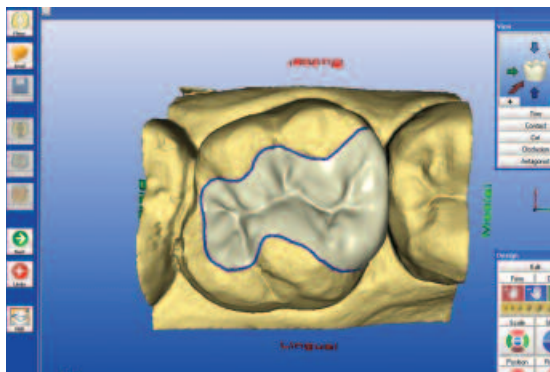


Figure 4—Biogeneric proposed restoration. What you see on the screen is what the restoration will be when milled.

(porosity, inconsistent firing, and cooling shrinkage stress).¹⁶ This will enhance clinical functional performance. The most common reason for ceramic performance failure is stress fracture propagating from inherent flaws.^{16,17}

Before bonding the restoration, finishing can be accomplished with polishing diamond wheels and paste or stain and glaze. The author prefers stain and glaze when the restoration replaces a cusp or is over 65% of the occlusal table. The glazing process elevates the functional strength of the ceramic restoration and offers the subtle esthetic tweaks to visually blend the restoration to the surrounding dentition (Figure 7).¹⁸ Once the stain and glaze process is mastered (often this can be delegated to the team), it will take approximately 15 minutes.¹⁷

Multiple Restorations: Case Report

The chairside CAD/CAM restorative process is effective for restoring multiple teeth in 1 appoint-

ment. The design process is similar to the single tooth application with the addition of the computer software's ability to sequentially design multiple teeth with 1 virtual die. After design of the first tooth in the quadrant, the software converts that tooth into a virtual tooth, facilitating design of the next restoration in the quadrant. The interproximal contacts are precisely set, allowing the operator to design multiple restorations with a single quadrant die capture.

In this case, 3 partial coverage ceramic restorations were replaced after 20 years (Figure 8). In restorative management, the first step before preparation is occlusal assessment for lateral interferences and necessary occlusal refinement to remove traumatic functional contacts. After placement of the imaging enhancement medium, the quadrant was imaged before preparation. The feldspathic restorations were removed and the margins and line angles were refined to meet the criteria for ideal CEREC preparation design.

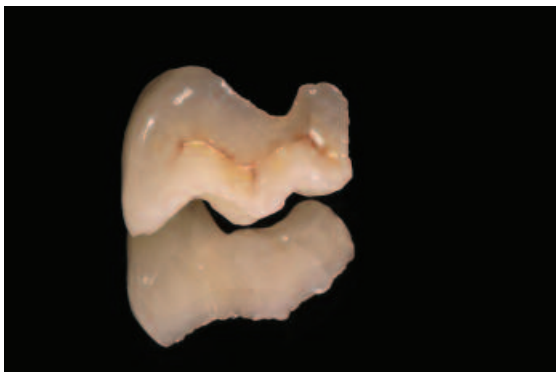

Figure 5—Completed milled restoration finished with stain and glaze.

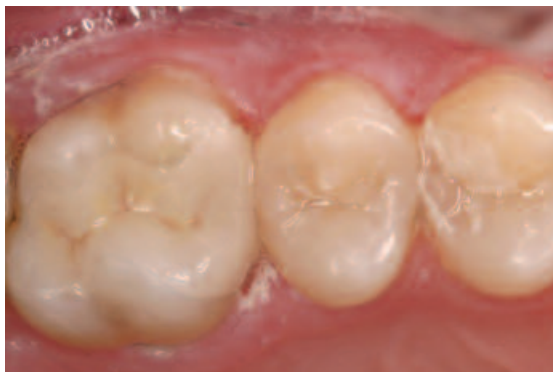

Figure 6—Note precision of restoration try-in before bonding.

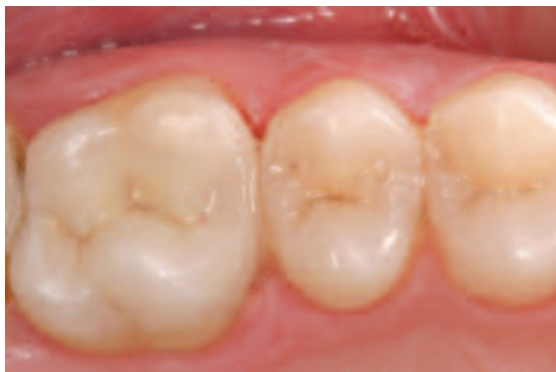

Figure 7—Completed CEREC restoration accomplished in 1 appointment.

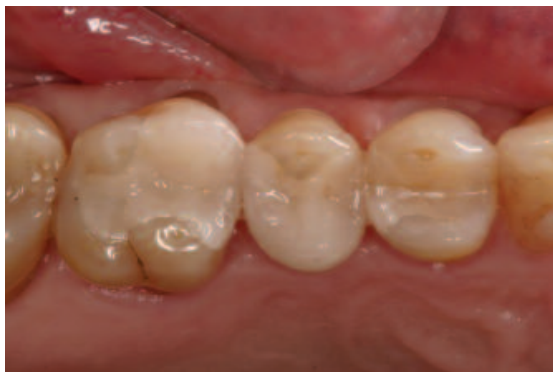

Figure 8—These ceramic onlays were completed 20 years ago.

The desired ceramic volume for CEREC restorations is 1.5 mm at the depth of the primary grooves and pits, 2 mm to 3 mm at the isthmus width, and 2 mm over working cusp replacement. Remaining cusps and the marginal ridge require dentin-supported enamel. Internal preparation design is best engineered with a smooth horizontal floor and shoulder margins perpendicular to occlusal loading forces. In this case, the interproximal margins were all prepared supragingivally. When finished margins present subgingival cervical circumstances, they are easily and safely managed with laser troughing.^{19,20}

After completion of the quadrant preparations, imaging enhancement medium was applied for precise 3D digital reproduction (Figure 9). The quadrant digital impression was captured from distal to mesial. The aperture of the CEREC camera allowed for the capture of each prepared tooth with enough digital overlap so the camera would precisely stitch together the images. In this case, 3 images were suf-

ficient to digitally construct the virtual quadrant die (Figure 10).

The CEREC software is able to align the preparation images, digital bite registration and preparation, and create a virtual articulator feature. The biogeneric tooth proposal aligned the occlusion to the preset parameters. Occlusion contact points were accurately positioned beyond the biogeneric proposal with the software design tools (Figure 11). Before milling, the mesial contour of the first molar was refined to create the ideal surface area and draw for the distal contact of the next tooth to be designed. Using this principle of interproximal design resulted in the quadrant restorations seating without need for interproximal adjustment of the multiple quadrant restorations.

Before milling, the designed restoration was positioned in the virtual gradated block to reflect the gradation of the tooth for desired clinical match. The chosen layered blocks were A3 for the first molar and A2 for the 2 premolars.

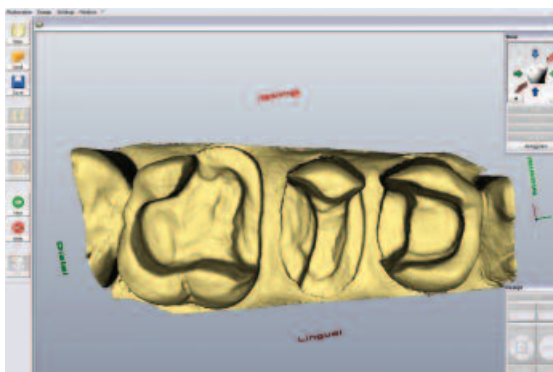


Figure 9—Virtual quadrant created from stitching 3 digital images.

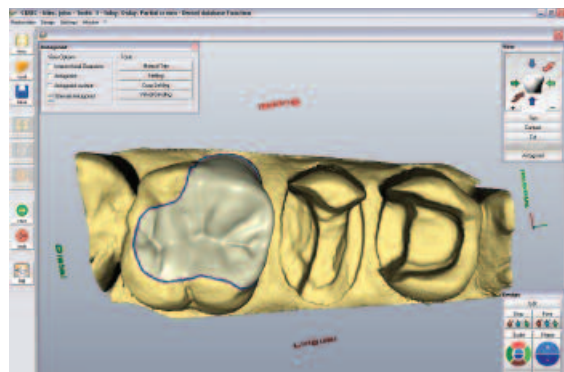


Figure 10—With the addition of a digital bite registration, the biogeneric CEREC software now proposes 95% or more of the restoration design.

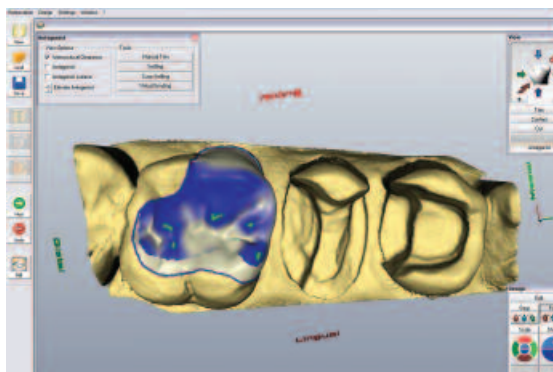


Figure 11—Occlusion contact points can accurately be positioned beyond the biogeneric proposal with the design tools.

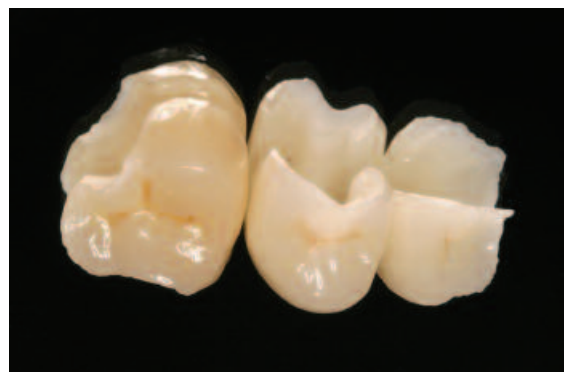

Figure 12—One-step stain and glaze will enhance the esthetic and functional properties of completed ceramics.

While the first molar was being milled, the computer software designed the next restoration in the quadrant. The quadrant feature virtualizes the first molar restoration, allowing the next tooth (the second premolar) to be designed in a manner similar to the first molar while the first molar is being milled. The software precisely tracked the interproximal design and contact so what was designed on the screen was produced in the milled restoration.

After milling, the restorations were seated to assess fit and complete any necessary adjustments. The finishing process involved a light polish of the margins with a diamond finishing wheel and inverted cone laboratory diamond to refine the primary grooves. After steam cleaning, light occlusal stain and glaze were applied for a single firing application (Figure 12).

All the restorations were bonded at the same time using an adhesive protocol for indirect ceramic restorations. After resin clean-up, the occlusion was adjusted where needed with finishing diamonds.

With proper preparation design, digital capture of the preparation, bite registration, and prepreparation images, minimal occlusal adjustment was required. Intraoral polishing of the margins and occlusal adjustment spots were completed with the ceramic polishing cups. No posttreatment symptoms were experienced by the patient (Figure 13).

Anterior Esthetic Restorations: Case Reports

Another application that the author has found beneficial for chairside CAD/CAM is anterior esthetic restorations. The single or double tooth situation can often be the ultimate esthetic challenge. Anterior tooth design is very similar to posterior capture and design protocols. The CEREC software comes with a library of multiple predesigned templates for both anterior and posterior full crowns. Once the preparation is digitally captured, the template style is chosen to best match clinical requirements or that of the wax-up. An additional option

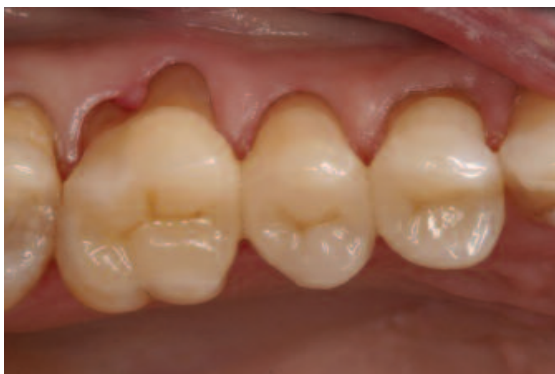

Figure 13—CEREC restorations reflecting the current standards of highly functional and esthetic ceramics restorations.

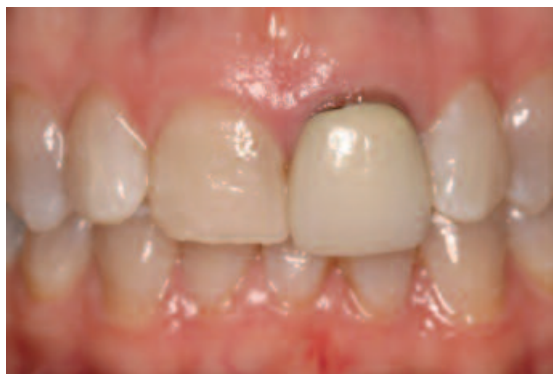

Figure 14—Pretreatment condition for anterior case.

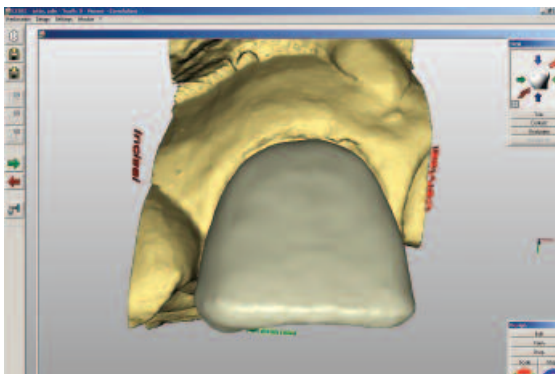


Figure 15—The software feature will transfer 95% of the wax-up design and proposal for the virtual restoration.

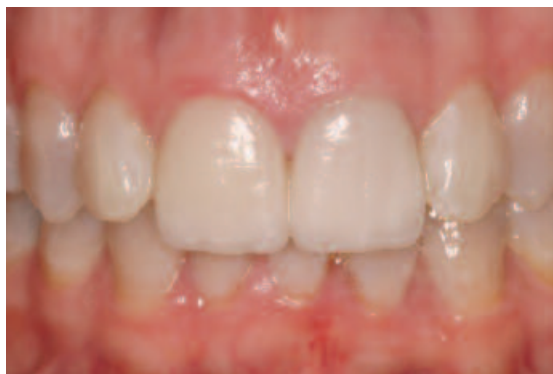

Figure 16—CEREC 3D has the ability to customize shape with the design tools and then characterize the surface texture and incisal edge to blend into the smile zone.

captures the contralateral tooth and the software will mirror the proposal for the design process. The author prefers Database design for full crowns and Correlation tooth scan of the wax-up or mock-up for veneers. The following 2 cases will demonstrate each of these approaches.

Anterior Case 1—Correlation Mode

The esthetic restorative treatment plan in this case was to veneer the right central incisor and retreat the porcelain-fused-to-metal on the left central with full all-ceramic restorations (Figure 14). The patient wanted to keep her natural look and felt the asymmetry of the adjacent laterals and canines made a natural harmonious appearance.

The esthetic diagnostic desires of this case were proposed with a diagnostic wax-up, which was then digitally captured and stored in the tooth catalogue for the case (Figure 15). After tooth

preparation and digital impression, the software correlated the wax-up over the digital preparation as the tooth proposal for both restoration designs.

The secret for a smooth reproduction of the wax-up is digitally capturing the wax-up proposal and preparation with identical alignment of the CEREC camera. A 60° angle to the long axis of the tooth acquired the labial and incisal surfaces of the wax-up. This acquisition principle precisely reproduced the primary and secondary contours on the labial surface, labial emergence profile, and the mesial and distal incisal embrasures of the wax-up. A digital bite registration for the full crown on tooth No. 9 facilitated the design completion for the lingual surface.

Restorations were milled with a layered block. Final surface texturing and contouring were accomplished with laboratory diamond burs before stain and glaze. Blending restored teeth to a natur-

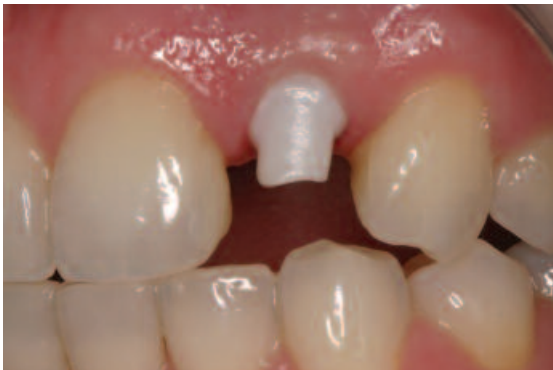

Figure 17—With the CEREC 3D technology, there are tools to simplify the matching process.

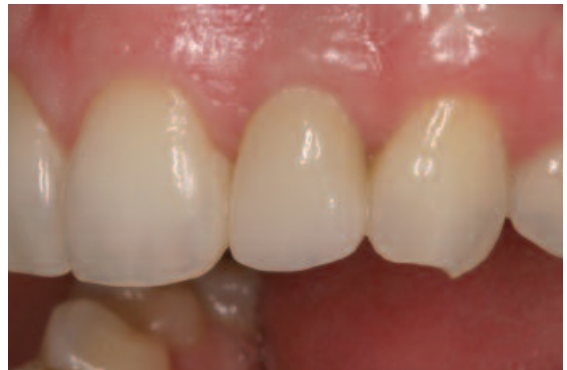

Figure 18—Most of the tooth design and shape is created through the CEREC 3D design and milling process. With a few additional finishing applications, the ceramics are stained and glazed for the final blending process.

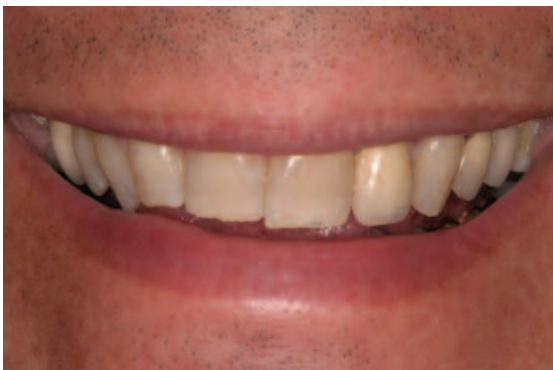

Figure 19—Primary objective with this case began with preparations to facilitate cant correction, create thinner centrals, widen buccal corridors, and design restorations to embrace golden proportions.

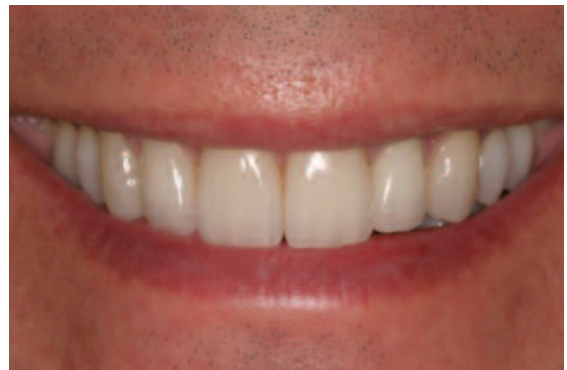

Figure 20—Final smile zone restorations designed and milled with CEREC and esthetic prelayered ceramic blocks.

al dentition was significantly enhanced by reproducing the surface texture (tertiary contours) (Figure 16).

The final clinical blending of the teeth in this case was choosing the appropriate resin bonding cement. The stump of the left central was several shades darker than the left veneer stump. With the combination of thicker ceramic (an additional 0.3-mm thicker for each shade darker) for the crown and a higher value resin, the stump color influence between the veneer and crown was neutralized (Variolink Veneer 0-transparent for the left veneer and +3-high value for the crown).

Anterior Case 2—Database Mode

With the zirconium implant abutments, CAD/CAM ceramics can be systematically designed and beautifully matched in a single appointment. This implant case was completed with the Atlantis implant system. The implant abutment was digitally captured, and a Database mode design and digital bite registration were used for the tooth proposal (Figure 17). The software design tools provided full control when positioning the proposed tooth. Finishing contours were accomplished with the virtual wax spatula Form Tool to recreate the emergence profile with the adjacent teeth. The virtual tooth design for a single tooth can be accomplished in 3 to 4 minutes. The full anterior crown was milled in 5 minutes.

The cementation on the zirconium abutment was accomplished with Multilink Automix, which bonds to zirconium and the ceramic etched, silane-prepared restoration (Figure 18). Because we were faced with more biomechanical demands in this case, a thin layer of ceramic was fired on the zirconium abutment and bonded on with ceramic-to-ceramic strength resin assembly.²¹

Conclusion

Chairside CAD/CAM restorations have a broad clinical application based on the clinician's skill and experience with all-ceramic restorations. The primary clinical limitations are isolation requirements for sound adhesive technique and occlusal space limitation for proper preparation and ceramic vol-

ume design to meet the clinical biomechanical demands of the clinical application.

The chairside CAD/CAM industry now has the ability to mill and finish lithium disilicate glass ceramics for the more functionally demanding zones in the mouth that require high strength, such as first and second molars.²² If there is limited clinical space to meet sound ceramic engineering design, the operator can still use the CAD/CAM technology to capture and mill out the restoration in a plastic block for gold casting or send the digital impression via e-mail to a specialized CAD/CAM laboratory to complete the fabrication of the gold restoration.

With the technological advancements in chairside CAD/CAM dentistry and materials, the operator is able to restore most conservative and esthetic indirect restorations (Figures 19 and 20). The limitations are no longer in the precision of the CEREC system. The limitations are now primarily in the expectation and skill experience of the operator.

References

1. Estafan D, Dussetschleger F, Agosta C, et al. Scanning electron microscope evaluation of CEREC II and CEREC III inlays [published correction appears in *Gen Dent*. 2003;51:583]. *Gen Dent*. 2003;51:450-454.
2. Nakamura T, Dei N, Kojima T, et al. Marginal and internal fit of CEREC 3 CAD/CAM all-ceramic crowns. *Int J Prosthodont*. 2003;16:244-248.
3. Bindl A, Mörmann WH. Clinical and SEM evaluation of all-ceramic chairside CAD/CAM-generated partial crowns. *Eur J Oral Sci*. 2003;111:163-169.
4. Posselt A, Kerschbaum T. Longevity of 2328 chairside CEREC inlays and onlays. *Int J Comput Dent*. 2003;6:231-248.
5. Otto T, De Nisco S. Computer-aided ceramic restorations: a 10-year prospective clinical study of CEREC CAD/CAM inlays and onlays. *Int J Prosthodont*. 2002;15:122-128.
6. Martin N, Jedyakiewicz NM. Clinical performance of CEREC ceramic inlays: a systematic review. *Dent Mater*. 1999;15:54-61.
7. Bremer BD, Geursten W. Molar fracture resistance after adhesive restoration with ceramic inlays or resin-based composites. *Am J Dent*. 2001;14:216-220.
8. Hickel R, Manhart J. Longevity of restorations in posterior teeth and reasons for failure. *J Adhes Dent*. 2001;3:45-64.
9. Tinschert J, Zvez D, Marx R, et al. Structural reliability of alumina-, feldspar-, leucite-, mica-, and zirconia-based ceramics. *J Dent*. 2000;28:529-535.
10. Chen HY, Hickel R, Setcos JC, et al. Effects of surface finish and fatigue testing on the fracture strength of CAD/CAM and pressed-ceramic crowns. *J Prosthet Dent*. 1999;82:468-475.
11. Mehl A, Blanz V. New procedure for fully automatic occlusal surface reconstruction by means of a biogeneric tooth model. *Int J Comput Dent*. 2005;8:13-25.

12. Mehl A, Blanz V, Hickel R. A new mathematical process for the calculation of average forms of teeth. *J Prosthet Dent.* 2005;94:561-566
13. Mehl A, Blanz V, Hickel R. Biogeneric tooth: A new mathematical representation for tooth morphology in lower first molars [published correction appears in *Eur J Oral Sci.* 2005;113:499]. *Eur J Oral Sci.* 2005;133:333-340.
14. Dunn M. Biogeneric and user-friendly: the Cerec 3D software upgrade V3.00. *Int J Comput Dent.* 2007;10:109-117.
15. Schneider W. No compromises the new CEREC MC XL and inLab MC XL milling machines. *Int J Comput Dent.* 2007;10:119-126.
16. *CRA Newsletter.* 2001;25:3-4.
17. Chen HY, Hickel R, Setcos JC, et al. Effects of surface finish and fatigue testing on the fracture strength of CAD-CAM and pressed-ceramic crowns. *J Prosthet Dent.* 1999;82:468-475.
18. McLaren E. CAD/CAM all-ceramic restorations achieving ultimate esthetics: clinical and laboratory perspective. Paper presented at the Academy of Computerized Dentistry of North America Annual Meeting; June 2006; Scottsdale, AZ.
19. Andreana S. The use of diode lasers in periodontal therapy: literature review and suggested technique. *Dent Today.* 2005;24:130-135.
20. Haraszthy VI, Zambon MM, Ciancio SG, et al. Microbiological effects of 810 nm diode laser treatment of periodontal pockets [abstract]. Presented at the 35th Annual Meeting of the American Association for Dental Research; March 2006; Orlando, FL. Abstract 1163.
21. Jedynakiewicz NM, Martin N. CEREC: science, research, and clinical application. *Compend Contin Educ Dent.* 2001;22(6 Suppl):11-12.
22. Wiedhahn K. From blue to white: new high-strength material for Cerec—IPS e.max CAD LT. *Int J Comput Dent.* 2007;10:79-91.